

Histopathological Study of Three *Leishmania* Major Strains

ADNAN M. AMIN, PhD* and MAHROUSA A. KHEDR, MD**

Department of Parasitology, Faculty of Medicine & Allied Sciences, King Abdulaziz University, Jeddah, Saudi Arabia and Department of Pathology, College of Medicine, Alexandria University, Alexandria, Egypt***

ABSTRACT. Amastigotes count in inoculated foot pad and histopathological study of infected mice were performed to study three *Leishmania* major strains: the Senegalese strain *MHOM/SN/OOIDKI(SN)*, the Sudanese strain *MHOMISO/89/UG8(SO)*, and the Saudi strain *MHOMISA184/JISH(SA)*. Eight-week-old male *BALB/c* mice were divided into three groups. Each group was infected with one of the studied strains. Amastigotes in the inoculated foot of infected mice in the three groups were counted at 30 and 45 days using modified fluorescence diacetate/ethidium bromide viability test. The number of amastigotes in the SA group was found to be significantly lower than that of the other two groups at both durations. There was no significant difference between the number of amastigotes in the SN and SO strains at 30 days, but it was significantly higher in the SN group than that of the SD group at 45 days post-inoculation. In the animals studied, tissue samples were obtained from the skin, liver, spleen, and testes for gross pathological changes and histopathological evaluation. The SO strain started earlier and led a more aggressive course. The SN and SA strains were less aggressive. The SA strain showed changes at an earlier time and resulted in a more aggressive course of the disease. The SN and SA strains were less aggressive. The SA strain showed the most chronic course of the three.

Keywords: Leishmaniasis, Three strains, Histopathological changes.

Introduction

Leishmanias are parasitic protozoa of the order Kinetoplastida (family Trypanosomatidae). Transmission is predominantly by the bite of infected sandflies, *Lutzomya* and

Correspondence & reprint requests to: Dr. Adnan Amin, P.O. Box 1541, Jeddah 2J441, Saudi Arabia.
Accepted for publication: 18 October 1997. Received: 01 June 1997.

phlebotomus [1]. Leishmaniasis occurs in three clinical forms; namely, cutaneous or oriental sore, mucocutaneous or espundia, and visceral or Kala-azar depending on the species involved [1]. Leishmaniasis, formerly limited to certain endemic areas, nowadays due to migration of foreign workers and the increase in international tourism, is frequently reported in several parts of the world [1].

Leishmania major has a wide but patchy distribution in parts of India, central Asia, the Middle East, and parts of North Africa. The disease occurs in Afghanistan, Iran, Iraq, Kuwait, and the Arabian Peninsula [1].

The present work describes the histopathological changes observed in experimentally-infected mice by three *Leishmania* strains and the results are discussed in relation to the pathogenesis of leishmaniasis.

Materials and Methods

Leishmania strains: The Senegalese strain MHOM/SN/00/DKI and the Sudanese strain MHOM/SD/89/UG8 were both obtained from the Royal Tropical Institute, Amsterdam, Holland. The Saudi strain MHOM/SA/84/JISH 118 was provided by King Faisal Specialist Research Center, King Faisal Specialist Hospital, Riyadh, Saudi Arabia. All three strains were maintained by culture in biphasic media (USANRU) [5] and serial subpassages into foot pads of BALB/c mice accordingly.

Experimental animals: Animals used in the present study were 8-week-old male BALB/c mice inbred in the animal house affiliated to King Fahd Medical Research Center, Jeddah, Saudi Arabia and were fed ad libitum.

Infection of experimental animals: A standard inoculum of 10×10^6 promastigotes in 0.05 ml was injected subcutaneously into the left foot pad of the mice. This inoculum was obtained from a second subculture on the seventh day (stationary phase), as described previously [1]. The mice used were divided into three groups. Each group contained 30 mice infected with each strain, in addition to a fourth control non-infected group. Mice were killed by cervical dislocation and tissue samples were obtained from skin, liver, spleen, and testes for gross pathology and for histopathological examination using routine haematoxylin and eosin (H&E) staining techniques. Quantitative determination of amastigotes in the skin was done 30 and 45 days after infection using a modification of fluorescein diacetate/ethidium bromide viability test [8].

Results were statistically analyzed using student t-test and ANOVA according to methods described previously [9, 10].

Results and Discussion

Experimental studies on inoculated BALB/c mice (Table 1; Figures 1-2): Naked eye examination showed that the lesion in the 3 groups started by a swelling at the site of inoculation which was first detected in the SD group on the 8th day followed by the SA group on the 10th day and in the SN group where the swelling started on the 13th day postinfection, respectively.

TABLE I. Onset and incidence of inflammatory reaction of the three *L. major* strains in liver and spleen of infected mice at 30, 45, and 90 days post-infection.

Organ	30 days						45 days						90					
	SN (10 mice)		SO (10 mice)		SA (10 mice)		SN (10 mice)		SO (10 mice)		SA (10 mice)		SN (10 mice)		SO (10 mice)		SA (10 mice)	
	Changes	No	Changes	No	Changes	No	Changes	No	Changes	No	Changes	No	Changes	No	Changes	No	Changes	No
Spleen	Negative	10	Negative	2	Negative	10	Negative	2	Negative	2	Negative	2	Negative	9	C.+5	2	Negative	1.
	A.+I	8	A.+I	8	A.+I	7	A.+I	7	A.+I	5	A.+I	5	A.+I	1	A.+4	5	A.+I	4
Liver	Negative	8	A.+I	8	Negative	3	A.+I	"9	A.+I	6	A.+I	8	A.+I	5	A.+5	6	A.+I	5
	A.+I	2	A.+2	2	A.+I	7	A.+2	1	A.+2	2	A.+I	2	A.+2	5	C.+5	3	A.+2	5
									A.+3	1	A.+3	1			B.+4	1		
									C.+5	1	C.+5	1						

A.+1 : Intact macrophages with a single focus of under 30 organisms.

A.+2: Like A.+1 with organisms over 30.

A.+3: Intact macrophages, numerous organisms in a small part.

A.+4 : Like A.+3, but with numerous organisms in most parts.

A.+5: Like A.+3 but with numerous organisms throughout.

B.+1 : Intact macrophages, single necrosis and single focus of under 30.

B.+4 : Like B.+1, but numerous organisms in most parts.

8.+5 : Like 8.+1, but numerous organisms throughout.

C.+4 : Areas of lysis and necrosis of macrophages with extracellular parasites numerous in most parts.

C.+5 : Like C.+4, but parasites numerous throughout.

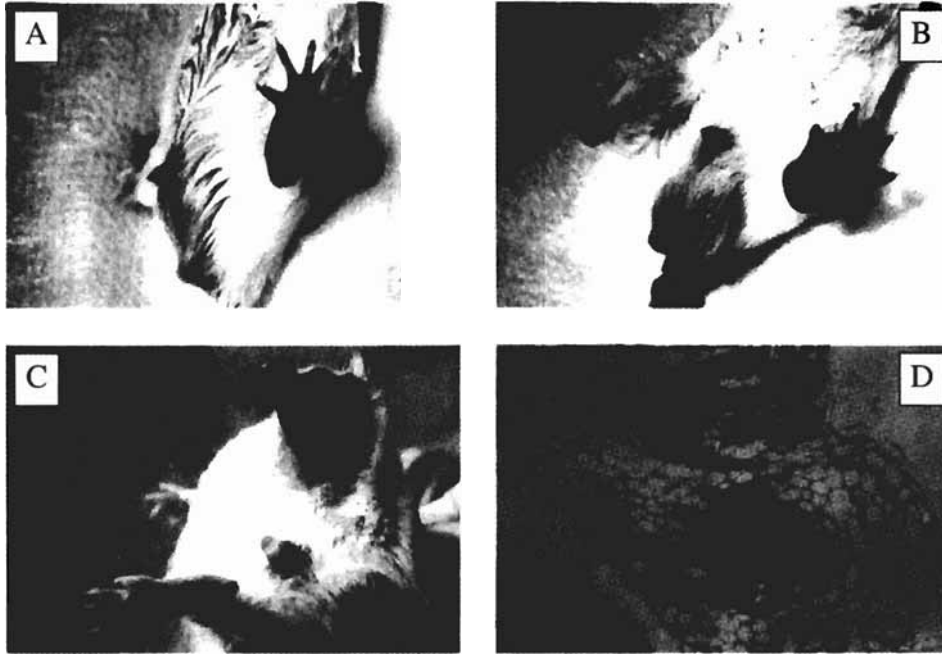


FIG. 1. Plate A: Left foot of a mouse infected by a Sudanese strain 15 days post-inoculation showing swelling in the foot pad.
 Plate B: Left foot of a mouse infected by a Saudi strain 28 days post-inoculation showing a crust.
 Plate C: Left foot of a mouse infected by a Sudanese strain 45 days post-inoculation showing complete gangrene and alopecia of the thigh.
 Plate D: Section in the testes of a mouse infected by a Senegalese strain at 90 days post-infection showing granuloma (g) in the periepididymal fat (f) (H&E x 1(0). epd: epididymis.

The local changes occurring in the inoculated foot including swelling, crust, gangrene, and amputation occurred first with the SD strain and were most severe throughout the course. The lesions in the SN strain started later than the SA group, yet its course was more progressive than the SA group which was very slow.

Histopathological examination of the skin of infected mice with the 3 strains showed the presence of inflammatory reactions composed of macrophages, lymphocytes, and polymorphs with areas of lysis and necrosis, but no plasma cells were detected. These changes indicate that the immune response in these animals is probably a T-cell mediated immune reaction as plasma cells usually found with B-cell mediated immune reaction. Conversely, Bray^[12] reported the presence of plasma cells in the lesion itself. The difference between the two studies may be related to the differences in the *L. major* strains used.

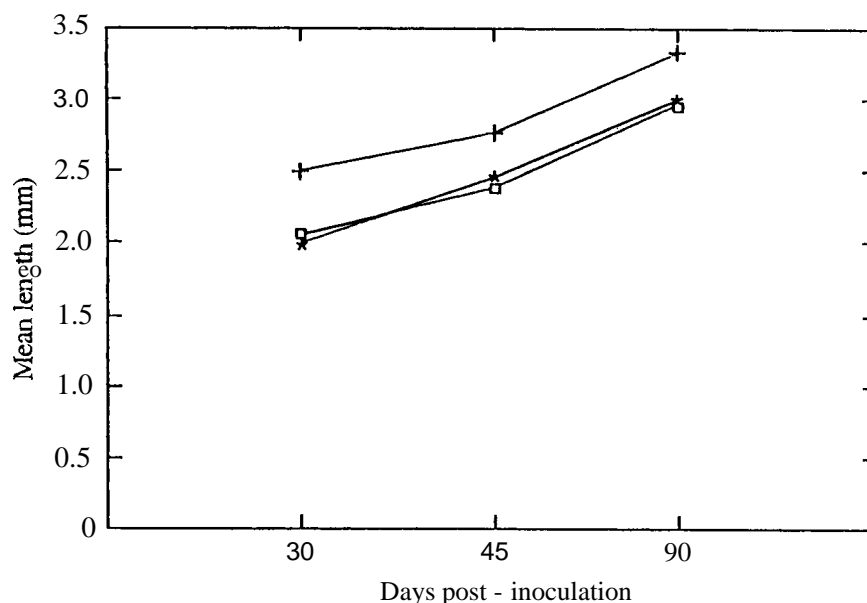


Fig 2. Mean length of the spleen at 30, 45, and 90 days post-inoculation in the three *L. major* infected groups. SN (O), SD (+), SA (*)

In the present study the lesion started at the site of inoculation, then visceralization occurred in the liver and spleen followed by multiple non-ulcerative cutaneous lesions on the other foot, upper limbs, tail, and penis, respectively. These changes occurred in the 3 strains but at different durations, with the SO strain always showing the changes earlier than the SN and SA strains. Visceralization was also reported by Abdelwahab *et al.* [13] and Youssef *et al.* [14], thus confirming our findings. The cutaneous metastatic lesions were non-ulcerative. They ulcerated only if predisposed by trauma due to friability of the inflamed skin. Scott and Farrel (1992) [15] reported multiple non-ulcerative lesions on the feet, face, and ears in BALB/c mice infected with *L. major* (Russian strain). By examining the liver, it showed affection in the 3 strains of *L. major*. The SO group was the first group affected (30 days post-inoculation) and was the severest throughout the course.

The lesions in the spleen were almost the same in the 3 groups at 30 days post-infection. At 45 days the SD group showed slightly more, but with no sharp differences between the other 2 groups. At 90 days post-infection, the SO strain was sharply aggressive while the SA and SN strains were nearly equal. Granulomatous reaction was the main lesion detected in the liver and spleen, formed mainly of macrophages with intra- and extracellular parasites. The presence of amastigotes in the liver and the spleen showed that the parasite was able to establish and multiply in the visceral, as well as in the cutaneous, sites. This observation is consistent with the study of Hill [16] who stated that *L. major* has the capacity to multiply at visceral and cutaneous sites at the same rates.

The testes and paratesticular regions were not affected at 30 days post-infection. At 45 days post-infection, one mouse in the SD group had granulomatous reaction in periepididymal fat while at 90 days post-infection, two mice were affected in each strain. Testicular

parenchyma tissue was not affected by the inflammatory reaction in any of the infected mice in the 3 groups. This can be explained by the resistant testicular blood barrier^[7]. Loss of hair (alopecia areata) in the thigh and face was also noticed in some of the mice in the 3 groups. This might be due to the destruction of the hair follicles in leishmaniasis^[1].

Amastigote count in foot pads of infected mice (Table 2; Figures 3-4): The number of amastigotes in the foot pads of mice varied depending on the pathological gross changes occurring in the foot.

TABLE 2. Mean number of amastigotes at 30 and 45 days post-in. culation for each of the infected groups.

Days Post-Infection	Strain								
	SN			SO			SA		
	X	SD	n	X	SD	n	X	SD	n
30	2453.8	242.05	10	2653.90	459.51	10	1002.3	206.40	10
45	3015.0	476.00	10	1976.43	1366.90	7	784.5	99.96	10
t-test	3.323*			1.4704*			3.003*		

X = mean, SD = standard deviation, n = number

* Statistically significant $P < 0.01$

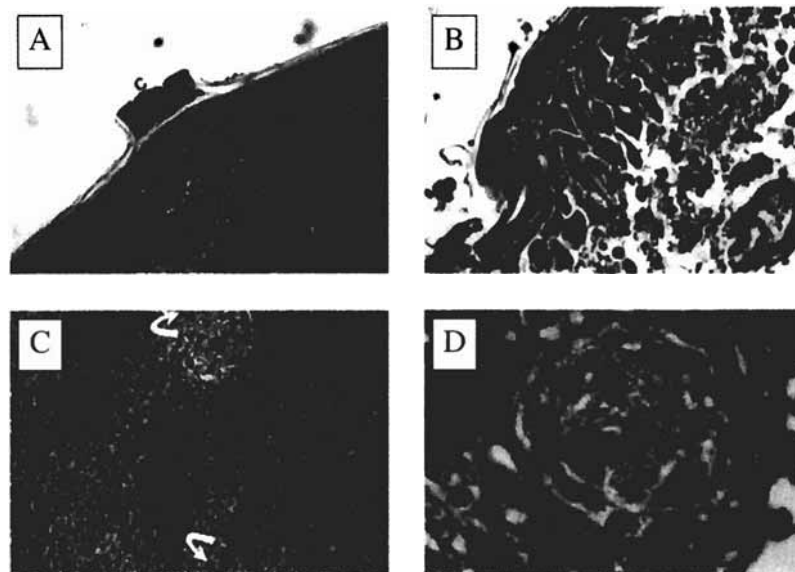


FIG. 3. Plate A: Section in skin of a mouse infected by a Sudanese strain 30 days post-infection showing a crust (c). The underlying dermis is infiltrated by inflammatory cells (i) (H&E x 160).
 Plate B: Section in the skin of a mouse infected by a Saudi strain of *L. major* 30 days after infection showing infiltration of epidermis (ep) by macrophages (), polymorphs, lymphocytes () and RBC (f). Amastigotes are abundant (H&E x 1000).
 Plate C: Section in the spleen of a mouse infected by a Sudanese strain 45 days post-inoculation showing granulomatous reaction containing macrophages and giant cells () (H&E x 200).
 Plate D: Section in the liver of a mouse infected by a Saudi strain 90 days post-infection showing intact macrophages with a focus of over 30 amastigotes (H&E x 1000).

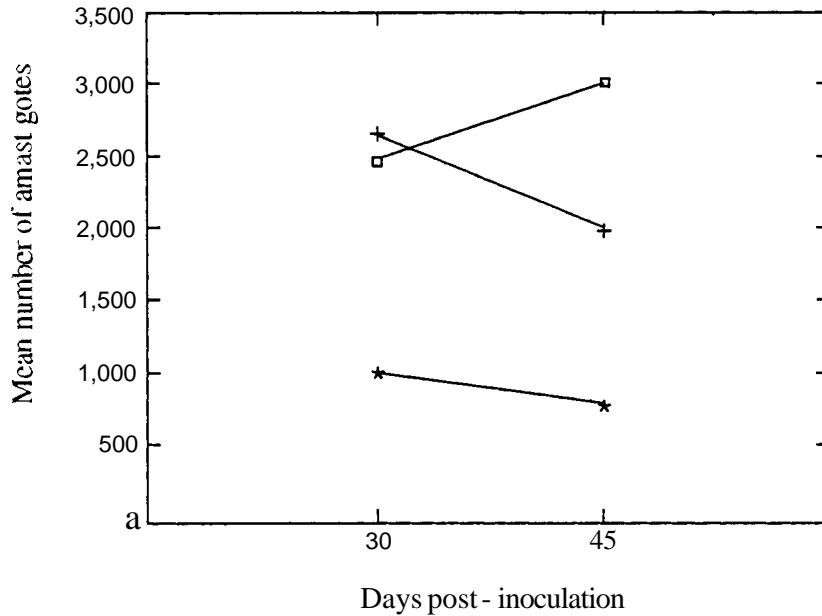


FIG. 4. Mean number of amastigotes in a foot pad of a mouse at 30 and 45 days post-inoculation in the three *L. major* infected groups. SN (0), SD (+), SA (*)

The mean number of amastigotes of the SN strain was significantly higher after 45 days than that of 30 days post-infection because the foot was markedly swollen with a huge crust in most of the mice. For the SD strain, the amastigote count at 30 days was higher than at 45 days post-infection because most of the mice had already developed gangrene by 45 days. Toxic effects of gangrene probably caused death and disintegration of some of the amastigotes. The number of amastigotes for the SA strain was higher on 30 days post-inoculation than on 45 days post-infection. This is probably because, on the 30th day, the reaction was still more acute than later in the course of disease.

Acknowledgement

We would like to express our deep thanks and gratitude to Dr. Azza Y. Negm, Prof. Nibal A. Hammouda, and Prof. Laila M. Abou-Samra for their advice and guidance in this study.

References

- [1] Lalnsor R, Shaw JJ. Evolution, classification and geographical distribution. In: Peters W, Killick-Kendrick R, eds. *The Leishmaniasis in biology and medicine*. Vol. I. London, Orlando: Academic Press, 1987; 1-20.
- [2] Maegraith B, Adams and Maegraith. *Clinical tropical diseases*. 8th ed. Oxford, London, Edinburgh, Boston: Blackwell Scientific Publication, 1984; 189-210.
- [3] Abdel-Wahab RM, Morsy TA, El-Garem AA, Bahgat A, Essa MH. Introduced cases of cutaneous Leishmaniasis in Egypt. *J Egypt Soc Parasitol* 1980; 1: 9-16.
- [4] Schnur LF. Old world cutaneous Leishmaniasis. In: Goldsmith R, Heyneman D, eds. *Tropical Medicine and Parasitology*. USA, Mexico, Canada: Prentice-Hall International, Inc., 1989; 286-295.

- [5] Walton BC, Shaw JJ, Lainson R. Observations on the in vitro cultivation of *Leishmania braziliensis*. *J Parasitol* 1977; 6: 1118-1119.
- [6] Sacks DL, Perkins PV. Identification of an infective stage of *Leishmania* promastigotes. *Science* 1984; 223: 1417-1419.
- [7] Wozencraft AO, Blackwell JM. Increased infectivity of stationary phase promastigotes of *Leishmania donovani*: Correlation with enhanced C3 binding capacity and CR3 mediated attachment to host macrophages. *Immunol* 1987; 60: 559-563.
- [8] Cennini P, Reeve AM, Neal RA. Two new techniques for quantitative determination of *Leishmania* amastigotes. *Trans Roy Soc Trop Med Hyg* 1989; 83: 194-195.
- [9] Castle WM. *Statistic in small doses*. 2nd ed. Edinburgh, London, New York: Churchill Livingstone 1977; 57-70.
- [10] Hanckens CH, Buring JE. In: *Epidemiology in Medicine*. Boston, Toronto: Little Brown and Company. 1977; 227-247.
- [11] Kumar V. Diseases of immunity--basic immunology. In: Robbins SL, Cotran RS, eds. Second edition. *Pathologic basis of disease*. Philadelphia, London, Toronto, Tokyo: WB Saunders Company 1979; 262-268.
- [12] Bray RS. Experimental Leishmaniasis of mammals. In: Peters W, Killick-Kendrick R, eds. *The Leishmaniasis in biology and medicine*. London, Orlando: Academic Press 1987; 425-463.
- [13] Abdel-Wahab RM, Morsy TA, Abdel-Rahim MI, Essa MH, Al-Alfy YE. The histopathological studies of *Leishmania major* infection in mice. *J Egypt Soc Parasitol* 1988; 18: 367-371.
- [14] Youssef NY, Eissa MM, Abou EI Naga IF, El-Gowhary S. Dissemination of *Leishmania* to organs of mice experimentally infected with *Leishmania tropica*. *J Egypt Soc Parasitol* 1996; 26: 230-238.
- [15] Scott PA, Farrell JP. Experimental cutaneous Leishmaniasis: disseminated Leishmaniasis in genetically susceptible and resistant mice. *Am J Trop Med Hyg* 1982; 2: 230-238.
- [16] Hill JO. Pathophysiology of experimental Leishmaniasis: Pattern of development of metastatic disease in the susceptible host. *Infect Immunity* 1986; 364-369.
- [17] Nistal M, Paniagua R. *Testicular and epididymal pathology*. Stuttgart, New York: Georg Thieme Verlag 1984; 14: 52.
- [18] Ridley DS. Pathology. In: Peters W, Killick-Kendrick R, eds. *The Leishmaniasis in Biology and Medicine*. Vol. II. London, Orlando: Academic Press 1987; 665-701.

دراسة هستوباثولوجية لثلاثة سلالات من الليشمانيا الكبيرة

عدنان أمين • ومحروسه خضر ••

* قسم الطفيليات الطبية 'كلية الطب والعلوم الطبية، جامعة الملك عبدالعزيز،

جدة، المملكة العربية السعودية

و** قسم علم الأمراض 'كلية الطب، جامعة الاسكندرية،

الاسكندرية، جمهورية مصر العربية

المستخلص . تمت دراسة التحليل الكمي للطور داخل الخلية بأقدام الفئران المصابة بجانب دراسة هستوباثولوجية في الفئران المصابة بثلاثة سلالات من *Leishmania major* السلالة السنغالية MHOMISN/00/DKI والسلالة السودانية MHOM/SAI84/JISH والسلالة السعودية MHOMISD/89IUG8 . أجريت هذه الدراسة على فئران ذكور بالغة من العمر ٨ أسابيع من فصيلة *BALB/c* . قسمت الفئران إلى ثلاثة مجموعات كل مجموعة تم عدوتها بسلالة من السلالات المذكورة . تم عد الطور داخل الخلية في أقدام الفئران المصابة بالسلالات الثلاث لليشمانيا باستعمال مادة الفلورسين ثنائي الأسيئات والإيثيديوم بروميد وقد وجد أن : عدد الطور أقل إحصائياً عند الإصابة بالسلالة السعودية إذا ما قورن بالسلالات الأخرى عند اليوم ٣٠ ، بعد الإصابة بالسلالة السنغالية إذا ما قورن بالسلالات الأخرى عند اليوم ٣٠ ، أكثر إحصائياً عند الإصابة بالسلالة السنغالية إذا ما قورن بالسلالات الأخرى عند اليوم ٤٥ . بدراسة التغيرات المرضية العينية وكذلك المجهرية في كل من الجلد والكبد والطحال والخصيتين بالفئران المصابة لوحظ ما يلي : أن الفئران المعدبة بالسلالة السودانية تظهر حنيتها الأخرى صحتي رقت مبكر بالمقارنة بالسلالتين الأخرتين . ويكون المرض أكثر شدة في هذه الفئران مما يؤدي إلى وفاتها بعد حوالي ٩٠ يوماً من الإصابة . يكون تطور المرض أقل شدة بكثير عند الإصابة بالسلالة السنغالية أو السعودية . تعتبر السلالة السعودية أقل السلالات الثلاثة من حيث الضراوة .