

Received: 2004.08.18
Accepted: 2004.11.05
Published: 2004.12.29

Tracheobronchomegaly associated with giant emphysematous bullae and bilateral pneumonia: Case report and review of the literatures

Omer S. Alamoudi

Department of Medicine, King Abdulaziz University Hospital, Jeddah, Saudi Arabia

Summary

- Background:** Tracheobronchomegaly (TBM) is a rare disease of unknown etiology. It is characterized by dilatation of the central airways, and recurrent chest infection. It is usually overlooked for sometime before final diagnosis can be reached, particularly, if the clinical presentation has been associated with other abnormal findings.
- Case report:** We present a case of TBM seen in a patient with bilateral giant emphysematous bullae and bilateral basal pneumonia. This was diagnosed accidentally by using high resolution computed tomogram of the chest, in a patient who presented with acute shortness of breath secondary to exacerbation of chronic obstructive pulmonary disease (COPD) that was misdiagnosed because of large bullae as a pneumothorax for which a chest tube was inserted. To the author knowledge and from extensive review of the literature, such combinations have not been previously reported.
- Conclusion:** TBM is a rare disease, and to reach the diagnosis a high index of clinical suspicion is essential particularly in middle aged patients who present with repeated chest infection. HRCT scan of the chest is usually diagnostic especially if the chest radiographs are normal.
- Key words:** Tracheobronchomegaly • Mounier-Kuhn syndrome • bulla • emphysema

Full-text PDF: http://www.crcpr-online.com/pdf/vol_5/6285.pdf

Word count: 1475
Tables: -
Figures: 4
References: 21

Author's address: Dr. Omer S. B. Alamoudi, Associate Professor, Consultant Pulmonologist, Dept. of Medicine, King Abdulaziz University Hospital, P.O. Box 80215, Jeddah 21589, KSA , phone: 9662-6408272, fax 9662-6408315, e_mail: dramoudi@yahoo.com

BACKGROUND

Tracheobronchomegaly (TBM) (Mounier-Kuhn syndrome) is a rare congenital disorder of unknown etiology affecting the lower respiratory tract. It is characterized by marked dilatation of transverse and sagittal diameters of the trachea and main-stem bronchi. It usually presents with ineffective chronic cough and repeated chest infection. The majority of TBM have been diagnosed between the third and the fifth decades with higher incidence in males [1-3]. However, few cases have been reported in preterm neonates and adolescence [4,5]. A familial tendency with a possible autosomal recessive inheritance has been seen in one family [3]. The condition is usually overlooked on the basis of chest radiographs alone; however, high resolution computed tomography (HRCT) of the chest is more sensitive in detecting such abnormalities [6].

CASE REPORT

A 46 year old black man with a 35 pack-year of cigarette smoking almost for 25 years presented to the emergency room of King Abdulaziz University hospital (KAUH) with acute exacerbation of COPD. For two weeks prior to presentation, he had productive cough with yellow sputum, fever, and progressive shortness of breath. In the past 6 years he experienced frequent episodes of COPD exacerbations for which he was hospitalized three times elsewhere. On two occasions of hospitalization a chest tube was inserted once on the right and once on the left to relief what it was thought to be a pneumothorax. On examination he was febrile, and the temperature was 38.5°C. He was dyspneic at rest, but had no cyanosis, palpable lymph nodes, clubbing, or edema. He was tachypneic with respiratory rate

of 32 breaths/minute. Pulse rate was 125 beats/ minute, and blood pressure was 160/70 mmHg. Examination of respiratory system showed bilateral reduction of chest expansion. Both lung bases were dull to percussion. There was decreased vesicular breathing, prolonged expiration, with scattered expiratory rhonchi and bibasilar crackles. White blood cell count was 19.3×10^3 mainly neutrophils. Erythrocyte sedimentation rate was 77. Urea and electrolytes were normal. ECG showed sinus tachycardia and right ventricular strain. Arterial blood gases analysis showed slight hypoxemia, pH=7.43, PCO₂=6.2 mmol/l, PO₂=7.5 mmol/l, oxygen saturation was 95% on room air. The initial chest x ray was interpreted by the emergency doctors as an acute chest infection with right pneumothorax and emphysema for which a chest tube was inserted in the emergency room (Fig.1). On 3rd day of hospitalization *Moraxella Catarrhalis* sensitive to cefuroxime was isolated from sputum. One week later he made an uneventful recovery with intravenous cefuroxime, steroid therapy and nebulized bronchodilator therapy. However, it had been noted that his chest tube was not functioning since its insertion, as there was no fluctuations could be seen with spontaneous or with maximal inspiratory effort. By reviewing his first and subsequent chest radiographs, there were signs of hyperinflation of the chest, bilateral large emphysematous bullae, bibasilar consolidation, and the chest tube was placed in apical region of the right lung but there was no sign of pneumothorax. HRCT of the chest was done for further evaluation and showed severe emphysema with multiple bullae of variable sizes mainly in the upper lobes compressing the right lung more than the left. The chest tube was placed outside the wall of the right emphysematous bulla. There was bilateral basal consolidation with air bronchogram. Interestingly, there was significant dilatation in the

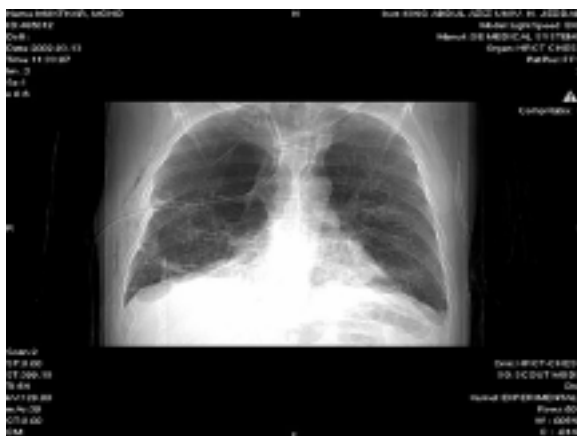

Figure 1. Supine chest radiograph, demonstrating numerous emphysematous bullae. The chest tube was inserted thinking that the patient has a pneumothorax. No dilated trachea could be seen.

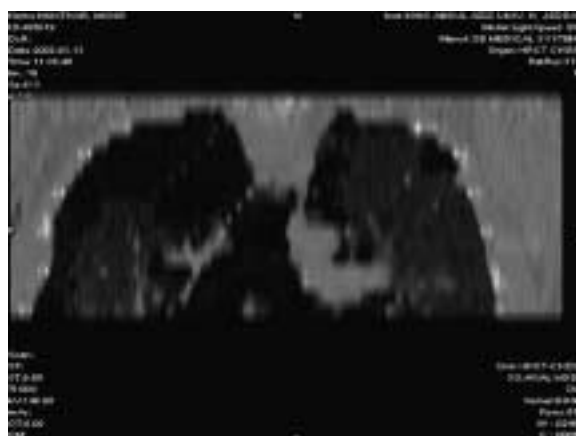


Figure 2. Coronal reconstruction CT scans, demonstrating wide trachea and main-stem bronchi.

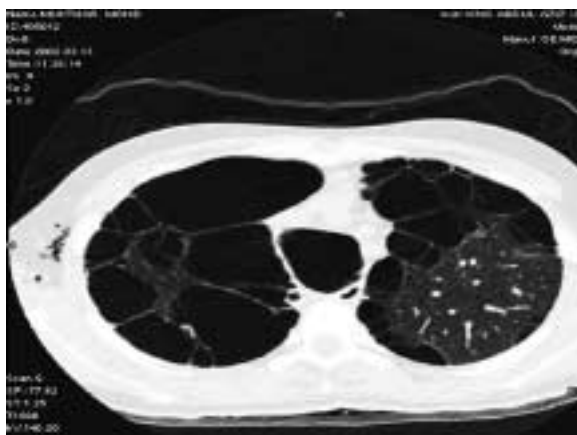


Figure 3. HRCT scan, showing multiple emphysematous bullae in the upper lobes and significantly dilated trachea.

transverse and sagittal diameters of the trachea, as well as, of the right and left main bronchi measuring up to 43 mm, 47 mm, 36 mm, and 34 mm respectively (Fig. 2, 3, 4). This particular finding was not present in the chest radiograph when reviewed by our radiologists.

DISCUSSION

Tracheobronchomegaly (TBM) is a rare disorder of the major airways characterized by marked dilatation of the trachea and central bronchi. It was first reported by Mounier-Kuhn in 1932 [7]. Its incidence is in the range of 0.5 to 1.5% with male preponderance and racial tendency in blacks [3]. The etiology of this syndrome remains unknown [1]. The pathological changes in the previous reported cases showed primary atrophy and loss of the elastic tissue, thinning of the collagen and smooth muscles of the trachea and major bronchi [2,3,8]. Patients with TBM usually present with recurrent chest infections, dyspnea, purulent sputum occasional hemoptysis, and chronic cough [1]. They also had an extended period of chest symptoms prior to first presentation and identification. Some patients have few or no symptoms and no apparent progression of disease. In our patient, he was symptomatic almost for 6 years during which he was hospitalized three times with repeated chest infection. However, he was a bit unfortunate as his large emphysematous bullae were interpreted wrongly on two previous occasions as well as at this time as a pneumothorax for which a chest tube was inserted. His TBM has not been recognized during previous hospitalizations as his giant emphysematous bullae most probably had drawn most of the attention. The diagnosis of TBM is usually based on the radiological findings that characterized by greatly increased tracheal caliber, measuring 35-50 mm or more in diameter [9]. Fraser, measured the caliber of bronchi using cinebronchography and found the diameter of

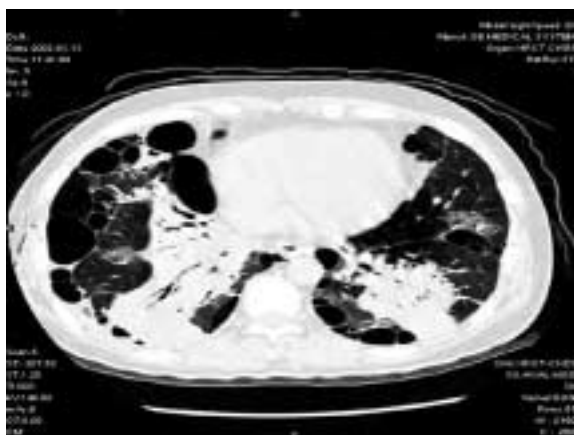


Figure 4. HRCT scan showing bilateral basal consolidation and bullae

trachea was normally between 10 to 27 mm in adults (mean 19.5 mm in males, 17.5 mm in females) [10]. This compares with values described for CT by Vock et al. in which the mean maximum normal coronal diameter of the trachea was 21.8 mm for men and 19.4 mm for women [11]. However, Katz et al using bronchography in 50 normal adult patients found the normal values for transverse diameter of the trachea (20.2 ± 3.4 mm) and right main stem (16.0 ± 2.6 mm) and left main stem (14.5 ± 2.8 mm) bronchi [12]. In our patient, TBM was recognized accidentally by using HRCT scan of the chest in which the transverse and sagittal diameters of his trachea was 43 mm, 47mm while the left and right main bronchi were 36 mm, and 34 mm respectively. The experience of MRI is still limited to one case report in the literature [13]. In TBM the trachea and major bronchi characteristically distend with deep inspiration and collapse on expiration. The central airways may virtually occlude with forced expiration or cough. This can be easily detected during fluoroscopic studies [6]. Pulmonary function tests commonly show an airflow obstruction with increased total lung capacity and residual volume. Restrictive pattern may also occur due to subsequent fibrosis. Bronchoscopy can be used to confirm the diagnosis in which a corrugated appearance occasionally can be seen in the significantly dilated trachea and main stem bronchi, and also the membranous portions tend to bulge dramatically between the widely separated rings during coughing or forced expiration [14]. TBM should be differentiated from other conditions that lead to marked dilatation of the bronchi such as Williams-Campbell syndrome, a rare form of congenital cystic bronchiectasis that result from a deficiency of cartilage in the fourth to sixth order bronchi. Although both diseases can result in significant bronchiectasis, patients with Williams-Campbell syndrome have normal caliber trachea and main

bronchi [15]. Allergic bronchopulmonary aspergillosis may produce significant enlargement of the central bronchi or central bronchiectasis. It usually occurs in patients with chronic asthma and cystic fibrosis. The radiological visualization of central, round, or varicoid bronchiectasis; large mucoid impactions and fleeting peripheral air space opacities is usually diagnostic [1, 16]. Pulmonary fibrosis in the upper lobes causes retraction of the tracheobronchial walls, leading to tracheomegaly. Chronic airway inflammation or infection may result in tracheobronchomalacia that presents with a diffusely flaccid and dilated airway. The association of TBM and giant emphysematous bullae is extremely rare and only few cases have been reported in the literature, and in one patient pneumothorax was the main presentation [17]. Our patient was unique in a way that TBM was associated with giant emphysematous bullae and bilateral pneumonia. The association of TBM with emphysematous bullae could be a coincidental finding. However, the loss of elastic tissue in both conditions may represent a possible association. Similarly to our patient, TBM was also reported once in association with Kenny-Caffey syndrome [18]. It is characterized by dwarfism, normal intelligence, and thickened bone cortices with small medullary cavities, ocular abnormalities and transient hypocalcaemia [18]. It also has been described in two patients who presented with

facial anomalies (ptosis and redundant skin fold of the upper lip) [5,19], and interestingly, one patient was infertile due to the association of an asthenozoospermia [19]. The therapeutic options for tracheobronchomegaly are limited as there is no specific therapy. Patients with TBM should be advised to quit smoking. Proper antibiotic and postural drainage is the usual therapy during chest infection. Bronchoscopy and tracheostomy or both may reduce the secretions and mucous plugging in some patients. Surgical correction has no role in TBM because of the diffuse nature of the disease. However, dynamic tracheal stent or tracheobronchial ednoprostheses have been used in two case reports with limited success [20, 21]

In conclusion; the diagnosis of TBM should be considered in patients with recurrent chest infection in middle aged patients. The diagnosis can be made easily with chest radiographs and CT scan of the chest.

Appendix

TBM	Tracheobronchomegaly
COPD	Chronic obstructive pulmonary disease
KAUH	King Abdulaziz University Hospital
HRCT	High resolution computed tomogram
MRI	Magnetic resonance image

REFERENCES

- Fraser RS, Muller NL, Colman N, Pare PD. Diagnosis of diseases of the chest, 4th ed. 1999. Philadelphia: Saunders.
- Woodring JH, Howard RS 2nd, Rehm SR. Congenital tracheobronchomegaly (Mounier-Kuhn syndrome): a report of 10 cases and review of the literature. *J Thorac Imaging*. 1991; Apr; 6 (2): 1-10.
- Johnston RF, Breen RA. Tracheobronchomegaly. Report of five cases and demonstration of familial occurrence. *Am Rev Respir Dis*. 1964; 91: 35-50.
- Bhutani VK, Ritchie WG, Schaffer TH. Acquired tracheomegaly in preterm neonates. *Am J Roentgenol* 1989; 152: 743-747
- Benesch M, Eber E, Pfleger A, Zach MS. Recurrent lower respiratory tract infections in a 14-year-old boy with tracheobronchomegaly (Mounier-Kuhn syndrome). *Pediatr Pulmonol* 2000; Jun; 29(6):476-479
- Shin MS, Jackson RM, Ho KJ. Tracheobronchomegaly (Mounier-Kuhn syndrome); CT diagnosis. *AJR*. 1988; 150: 777-79.
- Mounier-Kuhn P. Dilatation de la trachea; constatations radiographiques et bronchoscopiques. *Lyon Med*. 1932; 150: 106-09.
- Van Schoor J, Joos G, Pauwels R. Tracheobronchomegaly-the Mounier-Kuhn syndrome: report of two cases and review of the literature. *Eur Respir J*. 1991 Nov; 4 (10): 1303-1306.
- Bateson EM, Woo-Ming M. Tracheobronchomegaly. *Clin Radiol* 1978; 24:354-358
- Fraser RG. Measurements of caliber of human bronchi in three phases of respiration by cinebronchography. *J Can Assoc Radiol* 1961; 12:102-104
- Vock P, Spiegel T, Fram EK, Effmann EL. CT assessment of the adult intrathoracic cross section of the trachea. *J Comput Assist Tomogr*. 1984; 8:1076-1082.
- Katz I, Levine M, Herman P. Tracheobronchomegaly. The Mounier-Kuhn syndrome. *AJR*. 1962; 88: 1084-1094.
- Rindsberg S, Friedman AC, Fiel SB, Radecki PD. MRI in tracheobronchomegaly. *J Can Assoc Radiol* 1987; 38:126-128.
- Smith DL, Withers N, Holloway B, Collins JV. Tracheobronchomegaly: an unusual presentation of a rare condition. *Thorax*. 1994; 49:840-841.
- Marom EM, Goodman PC, McAdams HP. Diffuse abnormalities of the trachea and main bronchi. Pictorial Essay. *AJR*. 2001; 176: 713-717.
- Alamoudi OS. Allergic bronchopulmonary aspergillosis mimicking pulmonary tuberculosis. Case reports. *Saudi Med J*. 2001; Vol.22 (8): 708-713.
- Suzuki T, Kitami A, Hori G. Tracheobronchomegaly accompanied by bilateral giant pulmonary bullae and left spontaneous pneumothorax. Case report. *Scand J Thoracic Cardiovascular Surg*. 1994; 28(3-4): 153-155.
- Sane AC, Effmann EL, Brown SD. Tracheobronchomegaly: the Mounier-Kuhn syndrome in a patient with Kenny-Caffey syndrome. *Chest* 1992; 102:618-619
- Jain P, Dave M, Singh DP, Kumawat DC, Babel CS. Mounier-Kuhn syndrome. Case reports. *Indian J Chest Dis Allied Sci* 2002; 44: 195-198
- Pilavaki M. Tracheobronchomegaly roentgen findings and tracheal stent instrumentation. *Pneumologie* 1995; 49: 556-558.
- Lafaye-Robin ML, Muir JF, Kouziaeff N. Treatment of tracheobronchomegaly using Fretag prosthesis. *Revue Des Maladies Respiratoires* 1998; 15:291-294.